

ASSESSMENT OF THE EFFICACY OF TRIAMCINOLONE IN ORABASE AS SYMPTOMATIC TREATMENT OF ORAL LICHEN PLANUS

Durr e Sadaf^a, Arsalan Wahid^b, Quratul Ain^c, Tariq Javed^d, Saima Chaudhry^e, Farrukh Imran Mian^f

^aDemonstartor (Oral Medicine) University Medical & Dental College, Faisalabad.

^bAssistant Professor (Oral Pathology) University Medical & Dental College, Faisalabad.

^cAssistant Professor (Oral & Maxillofacial Surgery) Aziz Fatima Medical & Dental College Faisalabad.

^dAssistant Professor (Oral & Maxillofacial Surgery) University Medical & Dental College, Faisalabad.

^eAssistant Professor (Oral Pathology), University of Health Sciences, Lahore.

^fProfessor (Prosthodontics) University Medical & Dental College, Faisalabad, Pakistan.

ABSTRACT:

AIM: The aim of this study was to assess the efficacy of topical triamcinolone for the treatment of symptomatic Oral Lichen Planus.

MATERIALS AND METHODS: This study was conducted on eligible Oral Lichen Planus patients. 32 patients of symptomatic OLP were enrolled for the study. They were advised to apply an orabase containing 0.1% triamcinolone on lesions 3 times a day for the period of 4 weeks. Follow up visit and intraoral examination of the lesion was performed after completion of 4 weeks.

RESULTS: Study was completed by 32 patients. At follow-up examination, orabase containing 0.1% triamcinolone was found to be efficacious in terms of decreasing pain, improving color of the lesion, reducing lesion size and even decreasing the severity and activity of the OLP.

CONCLUSION: Orabase containing 0.1% triamcinolone is effective in treating symptomatic cases of Oral Lichen Planus.

KEYWORDS: Oral Lichen Planus, Triamcinolone, Topical Therapy,

CLINICAL RELEVANCE

SCIENTIFIC RATIONALE FOR THE STUDY: Oral Lichen Planus is associated with increased pain and discomfort in patients which affects their quality of life and performance. Triamcinolone is one of the most commonly used medicine for OLP but it has a mild efficacy in its treatment and doesn't fulfill the requirements of a satisfactory treatment.

PRINCIPAL FINDINGS: Orabase containing 0.1% triamcinolone have a good clinical efficacy in treatment of Oral Lichen Planus.

PRACTICAL IMPLICATIONS: Treatment of Oral Lichen Planus with orabase containing 0.1% triamcinolone can result in significant improvement in clinical parameters (Dimensions, Size, pain/burning sensation and clinical response) of the lesion.

INTRODUCTION:

Oral Lichen Planus (OLP) is a relatively common chronic inflammatory mucocutaneous disorder with a prevalence rate of 0.5 – 2.6 % that varies in different populations^[1]. Studies reported that 15 % of OLP patients develop skin lesions later in life as a systemic manifestation of OLP. It usually presents in 5th and 6th decade of life and has female predilection^[2].

Posterior region of the buccal mucosa is most commonly affected and it present in different forms like reticular, erosive and atrophic^[3]. Erosive form is subdivided into ulcerative and

bullous and atrophic is named as erythematous too because of its reddish appearance^[4]. Patients either remain asymptomatic and general dentist diagnose this condition in routine intra oral examination or they present with complaint of pain and burning sensation of oral mucosa but the long term follow up is

Corresponding Author:

Arsalan Wahid

Assistant Professor (Oral Pathology) University Medical & Dental College, Faisalabad.

Email: dr.arsalanmalik@gmail.com

recommended along with treatment because of its malignant transformation potential^[5].

Regarding the pathogenesis, it is believed to originate due to hyperactive immune response where basal epithelial cells are taken as foreign cells because of few changes on the cell surface however clinical response of different individuals are different in the same immune reaction^[6,7]. Other etiological factors may be hepatitis C and B virus, hypersensitivity to dental amalgam, spicy food and psychological stress and anxiety^[8].

Different topical and systemic agents are being used in the treatment of OLP but topical steroids are the mainstay of treatment. As we believe immune dysregulation as its main factor so topical steroids are used as 1st line of treatment. Other agents include retinoid, ultraviolet phototherapy and steroid sparing agents. Topical steroids have the least adverse effects as compared to systemic steroids and other agents so topical application is common in practice for the treatment of OLP. They have beneficial effects on lymphocytes and they repair the mucosal surface too^[9].

Topical agents are used in form of pastes, lotions, sprays and ointments. Steroid mouthwashes are specially used when the affected area is the posterior buccal mucosa. Usually physicians recommend 0.1 % Dexamethasone or 0.02 % Triamcinolone Acetonide applications for treatment of OLP^[9].

METHODOLOGY:

It's a Quasi experimental study, conducted in Department of Oral Medicine and Diagnosis, Madinah Teaching Hospital Faisalabad over a period of 2 months (1st April 2018 to 1st June 2018). Ethical approval of study was obtained from "Institutional Review Board (IRB)" of The University of Faisalabad, Faisalabad.

During the study period, all Oral Lichen Planus patients attending the Oral Medicine and Diagnosis Department of Madinah Teaching Hospital were screened for inclusion/exclusion criteria. General and medical inclusion criteria were: both males and females of any age, histopathologically proven cases of OLP and able to give informed consent. Patients who had taken any medication for OLP within 4 weeks before the start of study, pregnant/lactating

women and patients having history of lichenoid reactions to beta blockers, dapsone, oral hypoglycemics, NSAIDS, Pencillamine, phenothiazines, sulfonyleureas, gold salts or amalgam fillings were excluded from the study. Patients full filling the criteria were enrolled in the study and all the baseline parameters (Dimensions of lesion, Color of lesion, Pain or burning sensation and clinical response) and pre-operative photographs were recorded. (Table 1).

INTERVENTION:

At baseline visit the local irritant factors in the oral cavity which can aggravate the OLP were removed by doing basic oral procedures like scaling and root planning, restorations, rounding of sharp cusps and replacement of any ill-fitting appliances in all the patients to increase the reliability of the study.

The intervention in this study consisted of a topical medicine, orabase containing 0.1% triamcinolone. After 4 weeks examination of the lesion size, color, disease severity and VAS recording was repeated in all patients.

After 1 month of intervention, the follow up examination was performed and all the parameters (Dimensions of lesion, Color of lesion, Pain or burning sensation and clinical response) and post-operative photographs were recorded.

STATISTICAL ANALYSIS:

The data was coded and analyzed using SPSS software (version 20; SPSS Inc., Chicago, IL, USA). Mean \pm SD was used to summarize the numerical variables (like age, dimensions of lesion, VAS, subsite score, severity score and activity score); whereas frequency and percentage were employed to define the categorical variables (like gender, monthly income, comorbidity and systemic illness, smoking status and color of lesion).

The paired student *t* test was instituted to compare the mean difference in patients before and after treatment. For all inferential statistics in this study, *p* value ≤ 0.05 was taken as statistical significance.

RESULTS:

Study protocol:

Overall 67 patients were screened for the study and total 32 patients fulfilled the criteria and were enrolled for the study. (Fig 1).

Study parameters at baseline:

General characteristics recorded at baseline were age, gender, education status, monthly income and systemic illness. Regarding clinical parameters, dimensions and color of the lesion, pain or burning sensations and clinical response were observed. The age range of study subjects was between 30 to 77 years with overall mean \pm SD 48.22 ± 12.29 years. Out of 32

study subjects, fifteen (46.9%) were male and overall male to female ratio was 0.88:1. A statistically insignificant difference was found in baseline parameters.

Comparison of efficacy after intervention:

Table shows the difference in clinical parameters of intervention group from baseline to follow up. As compared to pre-intervention statuses, dimension of lesion, pain scores, subsite (A), severity (B) and activity (AxB) scores were significantly reduced as after application of intervention ($p < 0.05$).

Table 1: Lesion Parameters

Subsite Score (A)	
0	No lesion
1	Evidence of Lichen Planus
2	$\geq 50\%$ of buccal mucosa, dorsum of tongue, floor of mouth, gingiva, mucosal surface of lips, hard palate, soft palate oropharynx affected
Severity Score (B)	
0	Keratosis only
1	Keratosis with mild erythema (≤ 3 mm from gingival margin)
2	Marked erythema (e.g. full thickness of gingivae, extensive with atrophy or edema on non-keratinized mucosa)
3	Ulceration present
Activity Score (A x B)	
The activity score was calculated as the result of multiplying the subsite score (A) by the severity score (B)	

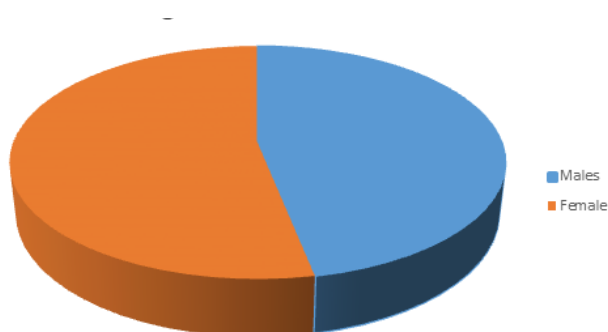


Fig 1: Gender Ratio in Patients

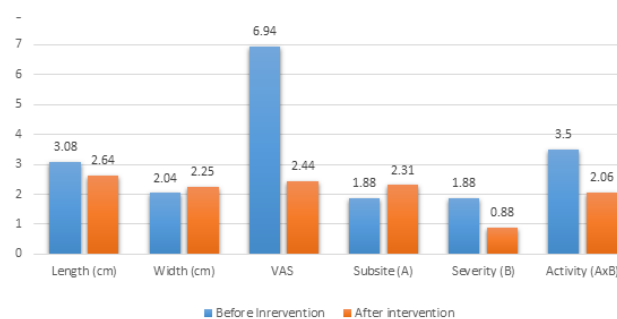


Fig 2: Comparison of efficacy in Patients

Table 2: Comparison of efficacy in Patients (n=32)

Parameters (mean±SD)	Before Intervention (n=32)	After Intervention (n=32)	t value	p-value*
Dimension				
Length (in cms)	3.08±1.32	2.64±1.31	(5.836),	0.001
Width (in cms)	2.04±1.37	2.25±1.22	(4.372),	0.001
VAS	6.94±1.69	2.44±1.20	(17.428)	0.001
Subsite (A)	1.88±0.34	2.31±0.47	(-2.406)	0.029
Severity (B)	1.88±0.95	0.88±0.62	(4.899)	0.001
Activity (AxB)	3.50±2.0	2.06±1.61	(3.032)	0.008

Data is shown in numbers followed by percentages in parentheses

*using paired student t-test; degree of freedom (df)=15

DISCUSSION:

Oral lichen planus (OLP) is a common chronic mucocutaneous disease which is autoimmune in nature and believed to affect mainly the basal keratinocytes of basement membrane. A very painful condition which makes it difficult for a person to eat, drink, speak and even to maintain a good oral hygiene^[10]. The main reason for not having its appropriate treatment is its unknown etiology^[11]. Several factors such as immunity, infections, psychological stress, genetics and endocrine glands are believed to be associated with this but undivulged pathogenesis is still disputed. According to a number of studies, OLP is a T-cell mediated autoimmune disease which is triggered by some unknown antigen either intrinsic or extrinsic^[12]. Evidence from some studies suggests that bacteria could be that antigen^[13]. Masaki presented some association of fungi with pathogenesis of OLP^[14]. Evidence of allergy to different chemicals and foods coming in contact with oral mucosa being responsible for OLP is also present^[8].

Topical application for the symptomatic relief of OLP is normally in use. Topical corticosteroids have been remained the 1st line of treatment since long. Other modalities have also been used including topical calcineurin inhibitors (TCIs) such as pimecrolimus, tacrolimus or

ciclosporin; retinoids such as isotretinoin; hydroxychloroquin; photochemotherapy; amitriptyline; thalidomide; amlexanox and traditional medicines such as curcumin, selenium-ACE combined with itraconazole, Bacillus Calmette-Guerin polysaccharide nucleic acid extract (BCG-PSN), propolis, glycyrrhizalabra and aloe vera but most effective topical regimen for symptomatic relief has not yet been found. Reports are there that OLP symptoms have been relieved by the use of antibiotics but despite the evidence of involvement of bacteria, fungi and allergic mechanism in pathogenesis of disease and worsening of symptoms, none has used the combination of steroid, antibiotic, antifungal and antihistamine as topical regimen for the relief of OLP symptoms.

Total thirty two (32) patients were studied in this study. Out of them, fifteen (46.9%) were male and the age range of study subjects was between 30 to 77 years with overall mean±SD age was 48.22±12.29 years. (Table 2)

This sample size is in consistent with various studies performed to observe the efficacy of different agents including corticosteroids and others for the symptomatic treatment of OLP^[15]. Arunkumar, *et al* in India designed a clinical trial comprising of 30 study subjects was designed in 2015 to evaluate the efficacy of pimecrolimus cream with triamcinolone acetate paste for

the symptomatic treatment of OLP.

Another similar clinical trial was conducted in 2016 by Sivaraman *et al* to compare the effect of triamcinolone, clobetasol propionate, and tacrolimus on symptoms of OLP. Their study sample size was also 30. They concluded that triamcinolone was better than tacrolimus in terms of effectiveness for relieving the symptoms of OLP^[16]. Joshy, *et al.* recently conducted a trial enrolling 27 clinically and histopathologically proven OLP patients to check the effectiveness of topical propolis for the symptomatic relief of OLP^[11]. In Egypt a clinical trial was conducted to compare Bacillus Calmette-Guerin polysaccharide nucleic acid extract with intralesional injections of triamcinolone acetonide and their sample size was 26^[12].

In addition to the severity of pain or burning sensation, color of the lesion, dimensions of the lesion (both length and width), severity and activity of the disease, others variables which were studied in this trial were education level, socioeconomic status, systemic history, medications in use and smoking status.

Baseline matching of all variables of patients was done at start of study. Evaluation of pain or burning sensation was done by using visual analog scale (VAS). Paired *t* test showed a statistically significant reduction of 4.5 with SD of ± 1.033 in mean VAS value. So it concluded that after intervention VAS pain scores were significantly reduced in our study population.

Dimensions of the lesion (both length and width) were measured using millimeter scale on baseline visit and on follow up visit. Mean difference (or reduction) in dimensions of lesion were then compared to assess the improvement by intervention. Mean length of lesion value (in cm) on baseline examination was 3.08 with SD of ± 1.32 , on follow up visit it was changed to 2.64 with SD of ± 1.31 while mean width of lesion (in cm) on baseline examination was 2.04 with SD of ± 1.37 and on follow up visit it was changed to 2.25 with SD of ± 1.22 . This shows that in intervention group size of the lesion reduced while in control group it remained the same.

Color of the lesions was noted on baseline visit and preoperative photographs taken. After 1 month on follow up visit, photographs again obtained in order to compare with preoperative photographs for change in color of lesion. According to results of our study color of the

lesion was improved in 100% of the patients which means triamcinolone in orabase can improve the color of lesion.

Severity and activity of the disease and its improvement was assessed by using a scale given by Escudier *et al* with some modifications^[17]. Scale is comprised of three subsets. Regarding the mean value of severity (B) of the disease in patients, paired *t* test showed a reduction of 1.00 with SD of ± 0.816 . It concluded that severity (B) of lesions was found to be reduced in patients of OLP. The difference was statistically insignificant [*t*(30)=1.414, *p*=0.168].

Regarding the value of activity (AxB) of the disease, paired *t* test showed a reduction of 1.438 with SD of ± 1.896 . So the activity (AxB) scores were significantly reduced in our patients. (*p*<0.05).

In order to find out new and a more effective remedy for symptomatic relief of OLP an RCT was conducted recently in India by Joshy, *et al.* They used topical propolis in comparison with topical triamcinolone. Both the propolis and triamcinolone were found to be equally efficacious in relieving pain and reducing erythema of OLP lesions in this study^[11].

CONCLUSION:

Due to the motivating results of present study it is concluded that triamcinolone in orabase is highly effective for the symptomatic relief of OLP. In addition, the lesion size and activity of the disease was also reduced by triamcinolone. Even the patients were more satisfied.

ACKNOWLEDGMENT:

Authors cordially acknowledge the services of staff of Department of Oral Health Sciences, Madinah Teaching Hospital, Faisalabad Pakistan for their selfless devotion in the conduction of this clinical trial.

REFERENCES:

1. Piñas L, García-García A, Pérez-Sayáns M, Suárez-Fernández R, Alkhraisat M-H, Anitua E. The use of topical corticosteroides in the treatment of oral lichen planus in Spain: A national survey. *Medicina oral, patologia oral y cirugia*

- bucal. 2017;22(3):e264.
2. Mostafa D, Tarakji B. Photodynamic therapy in treatment of oral lichen planus. *Journal of clinical medicine research*. 2015;7(6):393.
3. Wang J, Van der Waal I. Disease scoring systems for oral lichen planus; a critical appraisal. *Medicina oral, patologia oral y cirugia bucal*. 2015;20(2):e199.
4. Glick M. *Burket's Oral Medicine*, 12e: People's Medical Publishing House USA; 2015.
5. Gorouhi F, Davari P, Fazel N. Cutaneous and mucosal lichen planus: a comprehensive review of clinical subtypes, risk factors, diagnosis, and prognosis. *The Scientific World Journal*. 2014;2014.
6. Payeras MR, Cherubini K, Figueiredo MA, Salum FG. Oral lichen planus: focus on etiopathogenesis. *Arch Oral Biol*. 2013 Sep;58(9):1057-1069.
7. Ismail SB, Kumar SK, Zain RB. Oral lichen planus and lichenoid reactions: etiopathogenesis, diagnosis, management and malignant transformation. *J Oral Sci*. 2007 Jun;49(2):89-106.
8. D. Wray SRR, J. Gibson, A. Forsyth;. The role of allergy in oral mucosal diseases. *QJM*. 2000;93(8).
9. Ahadian H, Karbassi MA, Vahidi A, Owlia F. Comparison of two corticosteroids mouthwashes in treatment of symptomatic oral lichen planus. *Journal of Dentistry, Shiraz University of Medical Sciences*. 2012;13(2):49-53.
10. He Y, Gong D, Shi C, Shao F, Shi J, Fei J. Dysbiosis of oral buccal mucosa microbiota in patients with oral lichen planus. *Oral diseases*. 2017;23(5):674-682.
11. Joshy A, Doggalli N, Patil K, Kulkarni P. To evaluate the efficacy of topical propolis in the management of symptomatic oral lichen planus: A randomized controlled trial. *Contemporary clinical dentistry*. 2018;9(1):65.
12. Metwalli MI, Marei AM, Toama MA, Soliman MI, Fawzy MM. Bacillus Calmette-Guerin polysaccharide nucleic acid extract versus triamcinolone acetonide intralesional injection in the treatment of oral lichen planus: a comparative study. *Egyptian Journal of Dermatology and Venerology*. 2018;38(1):1.
13. He Y, Gong D, Shi C, Shao F, Shi J, Fei J. Dysbiosis of oral buccal mucosa microbiota in patients with oral lichen planus. *Oral Dis*. 2017 Feb 15.
14. Masaki M, Sato T, Sugawara Y, Sasano T, Takahashi N. Detection and identification of non *Candida albicans* species in human oral lichen planus. *Microbiology and immunology*. 2011;55(1):66-70.
15. Arunkumar S, Kalappanavar AN, Annigeri RG, Kalappa SG. Relative efficacy of pimecrolimus cream and triamcinolone acetonide paste in the treatment of symptomatic oral lichen planus. *Indian journal of dentistry*. 2015;6(1):14.
16. Sivaraman S, Santham K, Nelson A, Laliytha B, Azhalvel P, Deepak JH. A randomized triple-blind clinical trial to compare the effectiveness of topical triamcinolone acetonate (0.1%), clobetasol propionate (0.05%), and tacrolimus orabase (0.03%) in the management of oral lichen planus. *J Pharm Bioallied Sci*. 2016 Oct;8(Suppl 1):S86-S9.
17. Escudier M, Ahmed N, Shirlaw P, Setterfield J, Tappuni A, Black MM, et al. A scoring system for mucosal disease severity with special reference to oral lichen planus. *Br J Dermatol*. 2007 Oct;157(4):765-770.

	AUTHORS NAME	CONTRIBUTION	SIGNATURE
1	Durr e Sadaf EMAIL: durr.e.sadaf@iut.ac.ir	Data Collection & analysis	
2	Ahmed N. Shirlaw EMAIL: dr.ahmed.n.shirlaw@gmail.com	wrote up manuscript	
3	Qasim ul Ain EMAIL: qasimulain@gmail.com	wrote up manuscript	
4	Tasneem Saeed EMAIL: dr.tasneem.saeed@hotmail.com	wrote up manuscript	
5	Sadia Chaudhry EMAIL: chaudhry.s.p@iut.ac.ir	Final Approval to be submitted	
6	Fawzy MM. Marei EMAIL: m.marei@iut.ac.ir	Final Approval to be submitted	

Submitted for publication: 13.02.2019

Accepted for publication: 30.04.2019

After Revision